



The menisci and articular cartilage: a life-long fascination

Sebastian Kopf¹
 Manuel-Paul Sava²
 Christian Stärke³
 Roland Becker¹

- The menisci and articular cartilage of the knee have a close embryological, anatomical and functional relationship, which explains why often a pathology of one also affects the other.
- Traumatic meniscus tears should be repaired, when possible, to protect the articular cartilage.
- Traumatic articular cartilage lesions can be treated with success using biological treatment options such as microfracture or microdrilling, autologous chondrocyte transplantation (ACT), or osteochondral transplantation (OCT) depending on the depth and area of the lesion.
- Degenerative cartilage and meniscus lesions often occur together, and osteoarthritis is already present or impending. Most degenerative meniscus lesions should be treated first conservatively and, after failed conservative treatment, should undergo arthroscopic partial meniscus resection. Degenerative cartilage lesions should also be treated conservatively initially and then surgically; thereby treating the cartilage defect itself and also maintaining the axis of the leg if necessary.
- Tears of the meniscus roots are devastating injuries to the knee and should be repaired e.g. by transtibial re-fixation.
- The clinical role of 'ramp' lesions of the meniscus is still under investigation.

Keywords: arthroscopic partial meniscectomy; cartilage; conservative treatment; meniscus; meniscus 'ramp' lesions; meniscus repair; meniscus roots; osteoarthritis

Cite this article: *EFORT Open Rev* 2020;5:652-662.
 DOI: 10.1302/2058-5241.5.200016

Anatomy, function and epidemiology

The close anatomical and functional relationship of menisci and articular cartilage, in many parts very similar

organs, starts during their embryological development. Both articular cartilage and menisci, medial and lateral, originate from the interzone cells.¹ Menisci, also known as semilunar cartilages, cover a large part of the cartilage of the tibial plateau (Fig. 1), whereby the cartilage of the femoral condyle slides during movement of the knee above the menisci and the uncovered chondral parts of the tibial plateau. Menisci have several fixation points. The roots of the meniscus are the main stabilizers. Each human meniscus has an anterior and a posterior root. The roots are ligamentous structures connecting the meniscus horns to the tibial plateau. In addition, the posterior root of the lateral meniscus has two inconsistently existing stabilizers: the anterior and posterior menisiofemoral ligaments (Humphrey and Wrisberg), originally described by the German anatomist Josias Weitbrecht in 1742 (Fig. 2).²⁻⁴ However, there are more structures that provide stability to the menisci, for example, the transverse ligament connecting both anterior meniscus horns and the coronary ligament including the 'meniscus ramp'. The meniscus ramp is the part of the coronary ligament which connects the posterior horn of the medial meniscus to the tibial head.

Histologically, one of the main components of both cartilage and menisci is collagen: menisci contain mainly type I and articular cartilage type II collagen. Both are also dependent on collagen type III, which modulates the thickening of the aberrant fibres of type I collagen in menisci and type II collagen in cartilage.⁵

Besides their anatomical relationship, cartilage and menisci also have a close functional relationship. Menisci create congruity in the knee joint, allowing the cartilage of the femoral condyles to slide smoothly over the menisci and the tibial cartilage. Cartilage primarily takes compressive loads. Menisci also take compressive loads but mainly in Cooper zone 3.⁶ Furthermore, they support proprioception of the knee joint, providing stability, and lubrication. However, the main function of menisci is to convert

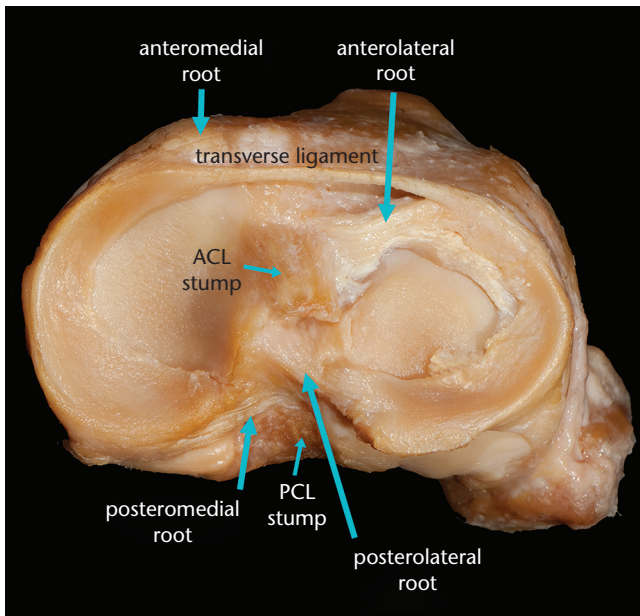


Fig. 1 Top-down view onto the tibial plateau showing the medial and lateral menisci with their roots and the transverse ligament.

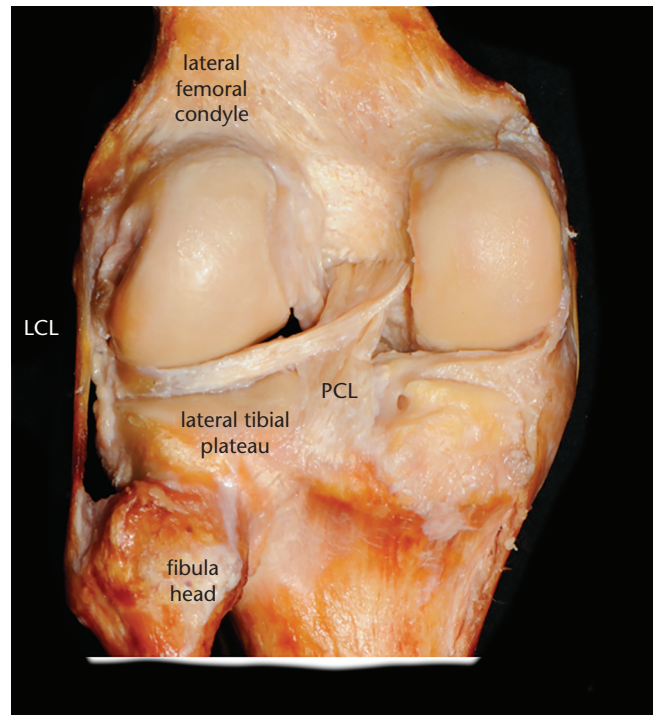


Fig. 2 View of the posterior aspect of the knee. The capsule is removed. The posterior meniscomfemoral ligament (Wrisberg) connects the posterior horn of the lateral meniscus with the medial femoral condyle.

Note. PCL, posterior cruciate ligament; LCL, lateral (fibular) collateral ligament.

tibiofemoral load into hoop stress through its longitudinal fibres, connecting the anterior and posterior meniscus roots. Disturbance in the structure of the menisci affects the distribution of forces and pressure load on the articular cartilage rises, leading to an early onset of osteoarthritis (OA). This close relationship between menisci and articular cartilage has also been demonstrated through the impact of degenerative and trauma-related meniscal injuries on the articular cartilage.⁷⁻⁹

Both cartilage and meniscus lesions have a high incidence. Their nature might be very different; thus, a nomenclature was established to avoid confusion.⁹ Degenerative meniscus lesions, mostly horizontally orientated, develop over time. Patients with these kinds of lesions have not experienced a trauma which is sufficient to tear their meniscus. These lesions can extend into flaps or complex lesions and are often associated with meniscus extrusion¹⁰ and osteoarthritis.¹¹ The prevalence of degenerative meniscus lesions increases with age. Among 50 to 59-year-old females, 19% of patients had a degenerative meniscus lesion on magnetic resonance imaging (MRI). Among 70 to 90-year-old male patients, 56% had a degenerative meniscus lesion.¹² About two-thirds of these lesions affect the medial meniscus. The prevalence of degenerative meniscus lesions increases with higher degree of OA. In a group of patients with OA of Kellgren and Lawrence (K&L) III^o or IV^o, 95% of patients had a damaged meniscus.¹² Patients with meniscus extrusion are even more prone to develop early OA (medial tibial plateau: (a) 2.1% per annum with extrusion vs. (b) 1.5%

without extrusion; lateral tibial plateau: (a) 2.6% vs. (b) 1.6%, respectively).¹³ This extrusion can occur in patients with degenerative meniscus lesions and with meniscus root tears. Besides degenerative meniscus lesions, there are also traumatic meniscus tears. These tears are mainly vertically orientated, for example, longitudinal (including bucket-handle) and radial tears.⁹ In general, patients report a significant trauma and are younger compared with patients with degenerative tears. Additionally, traumatic tears often occur concomitantly with ligament tears of the ipsilateral knee, e.g. a rupture of the anterior cruciate ligament (ACL). About 6% of injured knees sustain a traumatic meniscus tear resulting in 0.5 to 0.7 acutely injured menisci per 1000 individuals per year.¹⁴⁻¹⁶ The numbers of affected medial and lateral menisci in patients with a concomitant ACL tear vary significantly between studies. In general, it is accepted that in acutely injured knees with an ACL tear, lateral meniscus tears occur more frequently. By contrast, in chronically ACL insufficient knees, medial meniscus tears are more common.¹⁷⁻¹⁹ A similar discrimination is seen with meniscus root tears. Traumatic root tears mainly affect the posterolateral root in young patients with ACL tears; and, on the other hand, the degenerative meniscus root lesions including insufficiency (Fig. 3) mainly affect the posteromedial root in

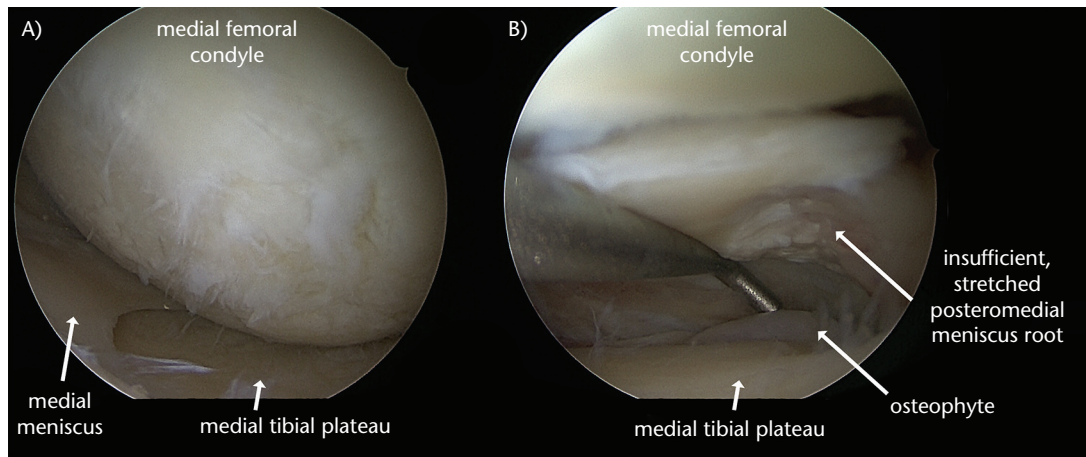


Fig. 3 (A) Severe damage of the entire medial femoral condyle and tibial plateau with cartilage degradation. (B) The reason for this degradation is the stretched, insufficient posteromedial meniscus root. The root was stretched by an osteophyte lying underneath the root.

older patients (often aged > 50 years), without a significant trauma but often associated with degenerative cartilage lesions of the medial tibiofemoral compartment (Fig. 3).

Similarly, articular cartilage defects are different in traumatic and degenerative lesions. To classify them, the classification of the International Cartilage Regeneration and Joint Preservation Society (ICRS) has been the widely accepted. To classify osteoarthritis of the knee, a rather general joint failure not just cartilage degeneration, the Kellgren and Lawrence and the Ahlbäck classifications have been widely accepted.^{20–22} Osteoarthritis is defined as a set of conditions that affect diarthroses, characterized through stress manifested at a cellular level and degradation of the extracellular matrix (ECM), promoted by injuries at both micro and macro level which activate a pathological repair response from the immune system, including the pro-inflammatory pathway.²³ Another definition proposed by the American College of Rheumatic and Therapeutic Criteria states that OA is a group of conditions that are heterogenic, which advances to joint-related symptoms and signs caused by the damaging of the articular cartilage structure alongside the damaging of the subsequently subchondral bone. What must also be understood is that illness is not the same as disease. Disease is characterized by signs and objectively quantified modifications, which in OA cases are: deformity, crepitus, restriction of movement and osteophytes. Illness refers to the subjective symptoms that a patient feels, such as mechanically characterized pain, joint stiffness and functional impairment. There are speculations that the threshold for clinical manifestation of OA is around 20% of joint affection.²³ The pathological abnormalities progress from a molecular stage through an anatomical one and end with the physiological alterations. Molecular

abnormalities such as altered proteins, metabolites and changes in the genomics can be demonstrated in early OA, long before any relevant modifications can be seen by X-rays, ultrasonography, MRI, and Positron emission tomography (PET) scans, during the so-called ‘silent period’ of time in which the patient also does not display any symptoms. Possible relevant markers that have been identified so far include: free type II collagen, urinary C-telopeptide of collagen II, racemized protein epitopes and deaminated protein epitopes. Also, the biochemical structure of the OA-affected articular cartilage differs from a normal one, creating a possible field for future research in this area. Anatomical abnormalities can be ascertained using different diagnostic modalities such as radiography, ultrasonography, MRI and PET scans. Through them the fibrillation of cartilage, loss of proteoglycans, apoptosis or proliferation of chondrocytes, malalignment of the joint, narrowing of joint space, osteophyte formation, presence of bone cysts and subchondral sclerosis can be observed. In the case of early OA, MRI has proven to be a great investigational tool. Thickening of cartilage, elevated T1 rho signal, meniscal degeneration and bone shape modifications are some of the objective findings. Ultrasonography can be also useful in diagnosing early OA through findings such as synovitis and angiogenesis, which occur secondary to the release of cartilage degradation products into the joint. The very last changes that appear in the development of OA are of physiological nature and refer to the abnormal biomechanical forces that are exerted at the affected joint level and their effects on it.²³ Cartilage lesions occur frequently. Out of 25,124 knee arthroscopies performed for different knee pathologies including meniscal tears, ACL reconstruction, acute trauma injuries, knee pain without known cause, etc.; 60% revealed different types of chondral lesions. From the aforementioned

Remnant of medial meniscus after arthroscopic partial meniscectomy with intact peripheral rim

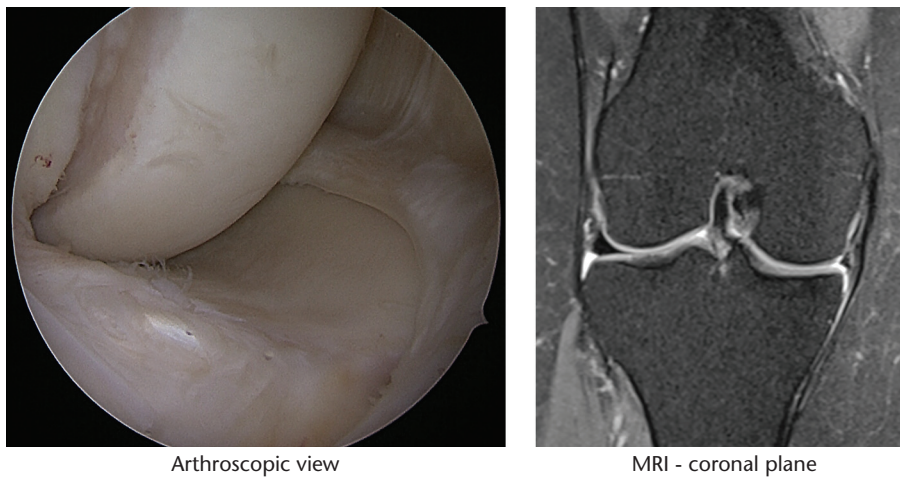


Fig. 4 These images are of a painful knee in a patient after arthroscopic partial meniscectomy.

60%, 67% of the patients had focal chondral/osteochondral lesions, 29% displayed OA, 2% were diagnosed with osteochondritis dissecans and 1% had other lesions.²⁴ The true incidence of chondral lesions though remains unknown due to the lack of symptoms. In terms of concomitant lesions, rupture of the medial meniscus ranks as first with 42%, followed by ACL injury with 36%. In terms of localization, the patellar surface and medial femoral condyle are the most common, at 36% and 34%, respectively.²⁴

Due to the fact that articular cartilage and menisci are subjected to the same forces and originate from the same embryonic interzone; a degenerative meniscus lesion tends to be associated with a pathological articular cartilage structure.²⁵ There are findings that support the idea that structural changes inside the knee joint can start either from the meniscus or the cartilage. Degenerative lesions of the meniscus can progress to structural lesions of the subchondral bone such as: increase of the subchondral bone density, subchondral bone cysts and bone marrow lesions, alongside cartilage damage, due to a rise in peak stress.⁵ Subsequently, radiographic findings support the idea that lesions of the articular cartilage have a key role in developing lesions of the subchondral bone, like subchondral oedema.²⁶ About 80% of middle-aged patients with meniscus lesions presented with typical symptoms such as general knee pain, pain during knee twisting and an untrustworthy knee (gives way). These symptoms matched the symptoms of patients with early radiological OA.²⁷ As already mentioned above, degenerative meniscus lesions are often associated with articular cartilage wear. In a recent study, 43% of patients who had undergone meniscus-related arthroscopies presented with early or advanced knee OA. About 75% of patients had presented with large cartilage defects: 44% retropatellar,

34% on the medial femoral condyle, and 18% on the medial tibial plateau.^{28,29} Based on these findings and similar findings of others, it was postulated that the damage inflicted on the articular cartilage tends to be localized and not uniformly distributed across the femoral and tibial articular surfaces. More specifically, tears in the medial meniscus body had a damaging effect on the articular cartilage lining the tibial central and anterior subregion. The same effect was observed in cases of posterior horn lesion, but in the posterior tibial subregion.³⁰ Out of all types of meniscus lesions, radial tears at the medial body were highly associated with loss of articular cartilage leading to OA.³¹

Interestingly, clinical syndromes are not mandatory in patients with degenerative meniscus lesions as data from the Framingham study showed, where prevalence of meniscus lesions was 31% in patients aged 50 to 90 years, and only 29% of these patients had knee complaints.³² These numbers increased significantly with increasing osteoarthritic changes. In patients with severe OA, up to 95% of patients had meniscus lesions (at least grade III) compared with 25% of patients without radiological signs of OA. In addition, there is a yet unknown link between tears in degenerated menisci and hand OA, with a 25% prevalence of damaged meniscus in the knew of subjects with zero finger joints affected by OA, 32% prevalence in those with one to two finger joints with OA, and 47% in patients with three or more finger joints affected. This is surely an interesting finding which may provide clues for future studies regarding tears in degenerated menisci and generalized OA.³³ Individual risk factors are, for example: female gender, older age, genetic pre-conditions, thickened intimal media of the carotid artery, tibial plateau fracture, ACL insufficiency and obesity.^{34,35} On the other hand, MRI examinations showed that weight loss

Follow-up MRIs after Partial Meniscus Replacement
3 months 12 months

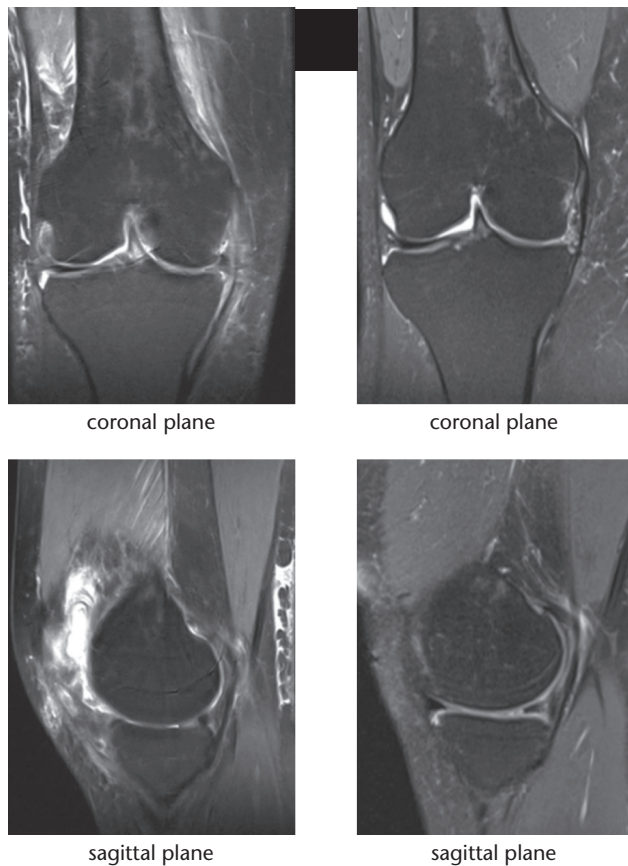


Fig. 5 Partial meniscal replacement with collagen implant: magnetic resonance imaging (MRI) three months post-operatively (left) and 24 months post-operatively (right). Note that MRI signal indicates successful integration of the implant in the posterior horn three months post-operatively while the implant was obviously absorbed in the intermediate portion of the meniscus.

resulting in a decreased BMI was associated with a slow-down of cartilage degeneration.³⁶

Treatment of meniscus and articular cartilage disorders

Treatment recommendations differ depending on the pathologies. For degenerative meniscus lesions, a paradigm shift has happened over the last 10 years, suggesting primarily conservative treatment, and arthroscopy with partial meniscus resection not until a conservative course of treatment has failed. This is true for patients with and without knee osteoarthritis.^{37–41} However, patients should be informed that with increasing degenerative changes of the knee the success rate decreases. It is important to check the limb alignment and treat it if appropriate. A Western Ontario and McMaster Universities Osteoarthritis index

(WOMAC) of > 40 points was identified as a predictor for failing conservative treatment and early arthroscopic partial meniscectomy.⁴² A recent European consensus agreed that the time period for conservative treatment should be at least three months.⁹ Thus far, no agreement exists about which kind of conservative treatment should be applied. Most studies used physiotherapy regimes or intra-articular corticosteroid injection. Perhaps a watch-and-wait approach is also an option. The role of non-steroidal anti-inflammatory drugs (NSAIDs) and others is unclear here, because the intake of analgesics was neither controlled nor monitored in these aforementioned randomized controlled trials (RCTs). These RCTs showed that conservative treatment is not inferior to partial meniscectomy; however, up to 35% of patients changed from conservative to surgical treatment during the trials (cross over). Some patients develop pain after arthroscopic partial meniscectomy, so that partial meniscus replacement might be an option, e.g. Actifit or collagen meniscus implant (CMI).^{43–45} These implants look initially similar to a meniscus and are tailored during surgery to fit into the meniscus defect. For both, an intact peripheral rim of the meniscus is critical to provide stability (Fig. 4).⁴⁵ K&L changes should not exceed II° at the time of implantation. Clinical results have been promising, including apparently stopping or at least slowing down progression of OA.⁴⁶ However, these implants have never been generally accepted because of considerable reported problems. Reasons for failure were a considerable resorption rate or decrease in size (Fig. 5), long rehabilitation and pending issues with availability because of regulatory authorities e.g. United States Food and Drug Administration (US FDA) or financial issues of the companies.^{46–48}

If the peripheral rim is interrupted, a *complete* meniscus replacement is necessary. Traditionally, a human meniscus allograft has been used in this circumstance. However, because of its high price, legal and administrative issues in many countries, rather small improvement in patient-reported outcome measures (PROMs), return to just low-impact activities in general as well as its questionable prevention of a further progress of OA, alternative solutions have been explored.^{49–52} One of these recent solutions is NuSurface, a free-floating, ring-shaped, polycarbonate-urethane meniscus implant (Fig. 6).^{47,53,54}

By contrast, the primary choice of treatment for traumatic meniscus tears is arthroscopic repair.⁵⁵ Self-induced repair rarely happens, except for small longitudinal tears of the posterior horn of the lateral meniscus in patients with a concomitant ACL repair or reconstruction. A biomechanical study showed that a longitudinal tear in the medial meniscus body decreased the in situ meniscus force under an axial load, supporting the necessity of meniscus repair to avoid articular cartilage damage.⁵⁶ For

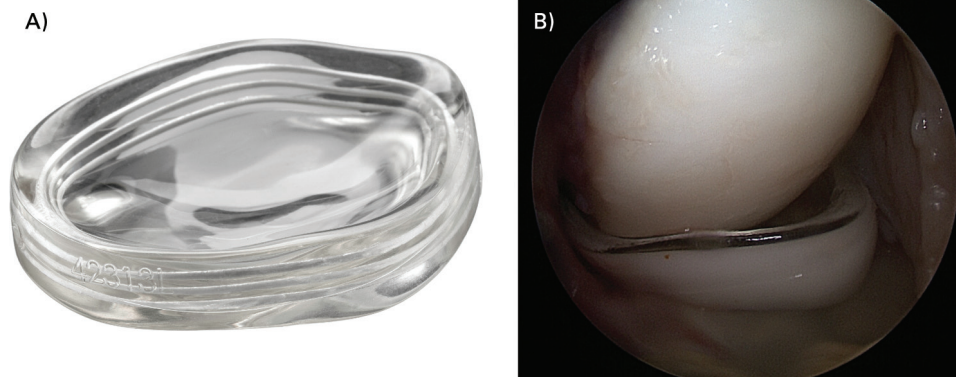


Fig. 6 One of the new solutions for complete meniscus replacement. (A) Schematic drawing of a free-floating, ring-shaped, polycarbonate-urethane implant (NuSurface by Active Implants™). (B) Arthroscopic photograph of the implant in place (the joint is filled with air in this photograph).

a long time the treatment of choice for traumatic meniscus tears was complete or partial resection, until recent studies showed the superiority of repair vs. partial meniscectomy with regard to the development of OA and return to the pre-injury level of activity. Tears should be repaired even if they are long or chronic.⁵⁵ In cases where an ACL reconstruction is not concomitantly performed, the medullary cavity should be opened, e.g. three holes into the femur anteriorly to the ACL attachment utilizing a microfracture awl or a drill bit.⁵⁷ General opinion is that longitudinal tears of Cooper zones two to zero should be repaired.^{7,8} This is true for men and women achieving similar results after five years of meniscus repair.⁵⁸ Repair is also the treatment of choice in patients with meniscus root tears; both degenerative and traumatic. The most commonly used technique is a transtibial root repair, and a biomechanical study suggested a two-tunnel technique (Fig. 7). The sutures should be placed into the meniscus horns. In cases with a concomitant ACL reconstruction, on the tibia the sutures of the meniscus root should not be pulled through the tibial ACL tunnel but through a separate tunnel in order to achieve physiological tension of the repaired meniscus (Fig. 7).⁵⁹

For degenerative meniscus root tears, it is important to pay attention to the grade of OA and leg alignment. Repair of roots is superior to conservative treatment and partial meniscectomy in knees with K&L grades I° and II°. There is debate about the usefulness of root repair in knees with K&L grade III°. There is agreement that root repair should not be performed with K&L grade IV°, because PROMS and progression were superior and progression of OA is significantly less following repaired roots.^{60–64} In cases with a varus knee in patients with a degenerative posteromedial root tear, a high tibial osteotomy (HTO) to unload the medial compartment should be considered.⁶⁵ By contrast, there is still debate about repairing the so-called ‘ramp lesion’ which occurs occasionally with ACL tears.

Biomechanical studies have proven the usefulness of a repair^{66,67} but there has been just one RCT so far showing no difference between leaving it alone or repairing it. The RCT is of lower quality and did not perform an a priori sample size calculation. Thus, it is unclear whether there was really no difference or whether the cohort was too small to find a difference.⁶⁸

Treatment of symptomatic cartilage lesions with chondral boundaries depends on the depths and the area of the lesion. Cartilage lesions > II° of ICRS classification are treated, lesions ≤ II° are left alone. Lesions of up to 25 mm² are treated with microfracturing or microdrilling, working best at the femoral condyle (Fig. 8). However, outcome improves up to two years and then it declines.⁶⁹ One reason is that these techniques generate fibrocartilage repair with a low content of hyaline cartilage resulting in a variable volume of substitute cartilage. Furthermore, autologous chondrocyte transplantation (ACTs) have a higher failure rate after previous microfracture compared to ACT for primary lesions.⁷⁰ Lesions above this size are better rather treated with ACT. ACT showed favourable results compared with microfracture after three years.⁷¹ However, ACT is not yet available in all countries. Furthermore, two surgeries are needed, and ACT is relatively expensive. Initially, cultured chondrocytes were transplanted into the defect, which was closed with a periosteum flap. Later on, a porcine type I/III collagen membrane was used to cover the cells fixed using fibrin glue or sutures during open surgery. The new generation can be applied arthroscopically by injecting a gel or applying small adhesive spheres which contain the cultured chondrocytes. A membrane to cover may not be necessary anymore. A further option to treat cartilage defects is osteochondral transplantation (OCT). It has shown good results for lesions up to 3 cm².⁷² However, after ten years, clinical results were inferior compared with ACT.⁷³ Today it is mainly recommended for cartilage lesions affecting subchondral bone structures.

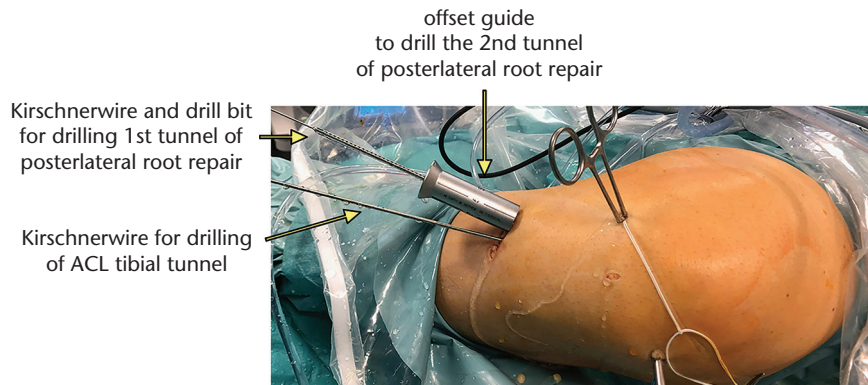


Fig. 7 Intra-operative picture of a knee in a figure-of-four position. Double-tunnel posterolateral root repair and an anatomical single bundle anterior cruciate ligament reconstruction (ACL-R) were performed. Tibial tunnels for ACL-R and posterolateral root repair were created independently to avoid compromising tensioning of the lateral meniscus.

Examples of Surgical Treatment of Cartilage Lesions

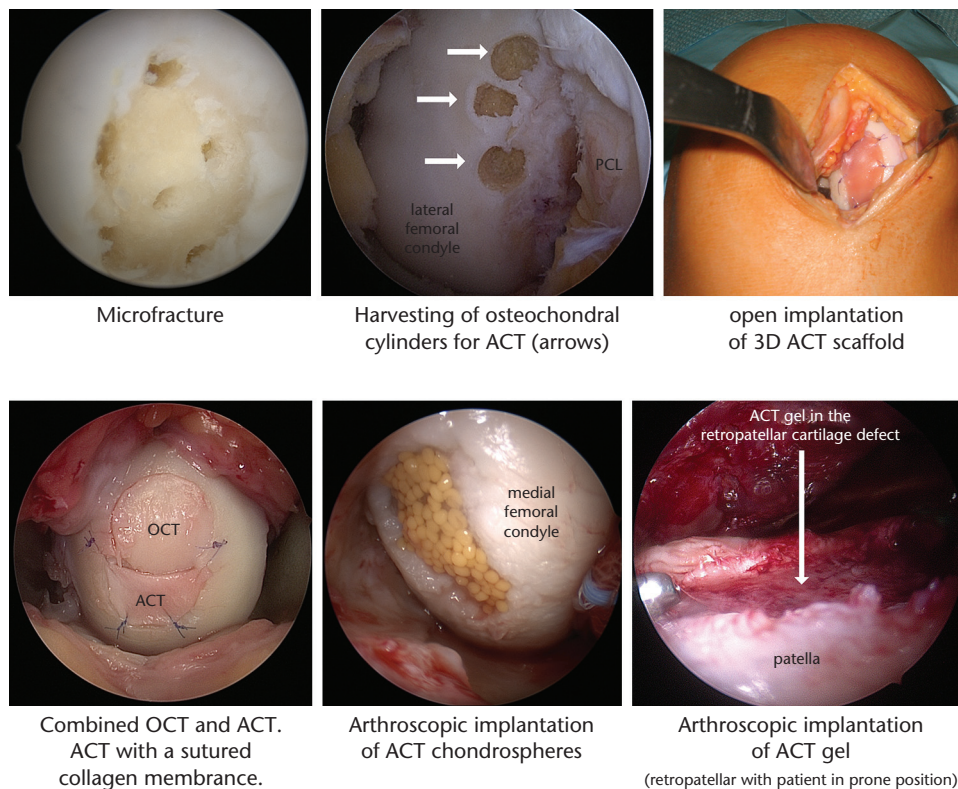


Fig. 8 Some examples of surgical treatment of cartilage lesions.
 Note. ACT, autologous chondrocyte transplantation; OCT, osteochondral transplantation.

and that are limited in size. One should keep in mind that treating properly concomitant lesions such as in meniscus tears, patella instability, and leg malalignment will improve the outcome and the survival of the cartilage treatment.

For degenerative symptomatic cartilage lesions and osteoarthritis, conservative treatment plays a bigger role.

Exercise, weight loss in overweight patients, cane use, bracing and NSAIDs were recommendations of the American College of Rheumatology/Arthritis Foundation.⁷⁴ Disease-modifying drugs showed varied results.⁷⁵ Intra-articular injections with corticosteroids (extended release), hyaluronic acid (high molecular weight) or platelet-rich plasma can help temporarily.^{76–79} Surgically, the above-mentioned

biological techniques are also used in patients with degenerative cartilage lesions. However, there is low evidence. In general, these techniques need good quality surrounding cartilage, which is often not present in patients with degenerative cartilage lesions. Furthermore, patients are older, and with age biological repair capacity decreases and concomitant lesions, e.g. degenerative meniscus lesions, are more frequent, further compromising the outcome. Thus, using these biological techniques in patients with degenerative cartilage lesions is not the standard nowadays.⁸⁰ Additionally, further techniques exist for degenerative cartilage lesions such as implanting a patient-specific metal plug into the chondral and bony defect.⁸¹ One of the most classical orthopaedic surgical techniques, correction of the leg axis to unload the affected compartment, is also one of the most effective. This is mostly done with a high tibial osteotomy (HTO). Nevertheless, more options exist, for example, the implantation of a spring on the medial side of the knee to unload the medial compartment.^{82,83} Biomechanically, the spring can lead to an unload of the medial compartment comparable to a 5° and 10° HTO. And of course, in severe OA or after failed prior OA surgeries, arthroplasty is an option, which will not be discussed in this article.

Conclusions

Cartilage and menisci have a close anatomical and functional relationship, which also plays a major role if one of them is damaged. Traumatic meniscus tears should be repaired to protect the articular cartilage and (partial) meniscus resection should be avoided. Degenerative meniscus lesions should be treated first conservatively, and only after failed conservative treatment (about three months) should arthroscopic partial meniscectomy be performed. Traumatic cartilage lesions should be treated depending on depth, affected area and possible bony pathology mainly by utilizing biological treatment options such as microfracture, OCT or autologous chondrocyte transplantation (ACT). For degenerative cartilage lesions, first-line treatment is conservative and second-line treatment is surgery with a variety of options, of which unloading the affected compartment is one of the most important.

AUTHOR INFORMATION

¹Center of Orthopaedics and Traumatology, Brandenburg Medical School Theodor Fontane, Germany.

²Orthopedics and Traumatology 2nd Department, Colentina Clinical Hospital, Bucharest, Romania.

³Department of Orthopaedic Surgery, Otto-von-Guericke University Magdeburg, Germany.

Correspondence should be sent to: Sebastian Kopf, Center of Orthopaedics and Traumatology, Medical School Brandenburg Theodor Fontane, Hochstr. 29, 14770 Brandenburg an der Havel, Germany.
Email: sebastian.kopf@pm.me

FUNDING STATEMENT

No benefits in any form have been received or will be received from a commercial party related directly or indirectly to the subject of this article.

ICMJE CONFLICT OF INTEREST STATEMENT

SK reports board membership of the journal of KSSTA and payment for lectures including service on speakers' bureaus, payment for development of educational presentations and travel/accommodation/meeting expenses unrelated to activities listed from Smith & Nephew, all outside the submitted work.

M-PS reports employment as a doctor at 'Sf.Pantelimon' Clinical Hospital, Bucharest and accommodation provided for a fellowship with Prof. Hirschmann at Department of Orthopaedic Surgery and Traumatology Kantonsspital Baselland-Bruderholz, Switzerland for the period 1 June 2020 to 31 August 2020, all outside the submitted work.

CS provides consultancy to Mathys Inc. outside the submitted work.

The other authors declare no conflict of interest relevant to this work.

OA LICENCE TEXT

©2020 The author(s)

This article is distributed under the terms of the Creative Commons Attribution-Non Commercial 4.0 International (CC BY-NC 4.0) licence (<https://creativecommons.org/licenses/by-nc/4.0/>) which permits non-commercial use, reproduction and distribution of the work without further permission provided the original work is attributed.

REFERENCES

1. Archer CW, Douthwaite GP, Francis-West P. Development of synovial joints. *Birth Defects Res C Embryo Today* 2003;69:144–155.
2. Weitbrecht J. *Syndesmology or a description of the ligaments of the human body*. London: W. B. Saunders Company Ltd.
3. Cho JM, Suh J-S, Na J-B, et al. Variations in meniscofemoral ligaments at anatomical study and MR imaging. *Skeletal Radiol* 1999;28:189–195.
4. Van Dommelen BA, Fowler PJ. Anatomy of the posterior cruciate ligament: a review. *Am J Sports Med* 1989;17:24–29.
5. Wang C, Brisson BK, Terajima M, et al. Type III collagen is a key regulator of the collagen fibrillar structure and biomechanics of articular cartilage and meniscus. *Matrix Biol* 2019;50945–053X(19)30373–7.
6. Anderson AF, Irrgang JJ, Dunn W, et al. Interobserver reliability of the International Society of Arthroscopy, Knee Surgery and Orthopaedic Sports Medicine (ISAKOS) classification of meniscal tears. *Am J Sports Med* 2011;39:926–932.
7. Paxton ES, Stock MV, Brophy RH. Meniscal repair versus partial meniscectomy: a systematic review comparing reoperation rates and clinical outcomes. *Arthroscopy* 2011;27:1275–1288.
8. Stein T, Mehling AP, Welsch F, von Eisenhart-Rothe R, Jäger A. Long-term outcome after arthroscopic meniscal repair versus arthroscopic partial meniscectomy for traumatic meniscal tears. *Am J Sports Med* 2010;38:1542–1548.

- 9. Beaufils P, Becker R, Kopf S, et al.** Surgical management of degenerative meniscus lesions: the 2016 ESSKA meniscus consensus. *Knee Surg Sports Traumatol Arthrosc* 2017;25:335–346.
- 10. Svensson F, Felson DT, Turkiewicz A, et al.** Scrutinizing the cut-off for ‘pathological’ meniscal body extrusion on knee MRI. *Eur Radiol* 2019;29:2616–2623.
- 11. Kumm J, Turkiewicz A, Zhang F, Englund M.** Structural abnormalities detected by knee magnetic resonance imaging are common in middle-aged subjects with and without risk factors for osteoarthritis. *Acta Orthop* 2018;89:535–540.
- 12. Englund M, Guermazi A, Gale D, et al.** Incidental meniscal findings on knee MRI in middle-aged and elderly persons. *N Engl J Med* 2008;359:1108–1115.
- 13. Teichtahl AJ, Cicuttini FM, Abram F, et al.** Meniscal extrusion and bone marrow lesions are associated with incident and progressive knee osteoarthritis. *Osteoarthritis Cartilage* 2017;25:1076–1083.
- 14. Hede A, Jensen DB, Blyme P, Sonne-Holm S.** Epidemiology of meniscal lesions in the knee. 1,215 open operations in Copenhagen 1982–84. *Acta Orthop Scand* 1990;61:435–437.
- 15. Maffulli N, Binfield PM, King JB, Good CJ.** Acute haemarthrosis of the knee in athletes. A prospective study of 106 cases. *J Bone Joint Surg Br* 1993;75:945–949.
- 16. Nielsen AB, Yde J.** Epidemiology of acute knee injuries: a prospective hospital investigation. *J Trauma* 1991;31:1644–1648.
- 17. Thompson WO, Fu FH.** The meniscus in the cruciate-deficient knee. *Clin Sports Med* 1993;12:771–796.
- 18. Bellabarba C, Bush-Joseph CA, Bach BR Jr.** Patterns of meniscal injury in the anterior cruciate-deficient knee: a review of the literature. *Am J Orthop (Belle Mead NJ)* 1997;26:18–23.
- 19. Ihara H, Miwa M, Takayanagi K, Nakayama A.** Acute torn meniscus combined with acute cruciate ligament injury: second look arthroscopy after 3-month conservative treatment. *Clin Orthop Relat Res* 1994;307:146–154.
- 20. Kellgren JH, Lawrence JS.** Radiological assessment of osteo-arthritis. *Ann Rheum Dis* 1957;16:494–502.
- 21. Kohn MD, Sassoon AA, Fernando ND.** Classifications in brief: Kellgren–Lawrence classification of osteoarthritis. *Clin Orthop Relat Res* 2016;474:1886–1893.
- 22. Petersson IF, Boegård T, Saxne T, Silman AJ, Svensson B.** Radiographic osteoarthritis of the knee classified by the Ahlbäck and Kellgren & Lawrence systems for the tibiofemoral joint in people aged 35–54 years with chronic knee pain. *Ann Rheum Dis* 1997;56:493–496.
- 23. Kraus VB, Blanco FJ, Englund M, Karsdal MA, Lohmander LS.** Call for standardized definitions of osteoarthritis and risk stratification for clinical trials and clinical use. *Osteoarthritis Cartilage* 2015;23:1233–1241.
- 24. da Cunha Cavalcanti FM, Doca D, Cohen M, Ferretti M.** Updating on diagnosis and treatment of chondral lesion of the knee. *Rev Bras Ortop* 2015;47:12–20.
- 25. Englund M.** The role of the meniscus in osteoarthritis genesis. *Rheum Dis Clin North Am* 2008;34:573–579.
- 26. Atik OŞ, Erdoğan D, Seymen CM, Bozkurt HH, Kaplanoğlu GT.** Is there crosstalk between subchondral bone, cartilage, and meniscus in the pathogenesis of osteoarthritis? *Eklemler Hastalıkları* 2016;27:62–67.
- 27. Hare KB, Stefan Lohmander L, Kise NJ, Risberg MA, Roos EM.** Middle-aged patients with an MRI-verified medial meniscal tear report symptoms commonly associated with knee osteoarthritis. *Acta Orthop* 2017;88:664–669.
- 28. Pihl K, Englund M, Lohmander LS, et al.** Signs of knee osteoarthritis common in 620 patients undergoing arthroscopic surgery for meniscal tear. *Acta Orthop* 2017;88:90–95.
- 29. Spahn G, Plettenberg H, Hoffmann M, Klemm H-T, Brochhausen-Delius C, Hofmann GO.** The frequency of cartilage lesions in non-injured knees with symptomatic meniscus tears: results from an arthroscopic and NIR- (near-infrared) spectroscopic investigation. *Arch Orthop Trauma Surg* 2017;137:837–844.
- 30. Chang A, Moio K, Chmiel JS, et al.** Subregional effects of meniscal tears on cartilage loss over 2 years in knee osteoarthritis. *Ann Rheum Dis* 2011;70:74–79.
- 31. Jarraya M, Roemer FW, Englund M, et al.** Meniscus morphology: does tear type matter? A narrative review with focus on relevance for osteoarthritis research. *Semin Arthritis Rheum* 2017;46:552–561.
- 32. Hwang JJ, Macinga D, Rorke EA.** Relaxin modulates human cervical stromal cell activity. *J Clin Endocrinol Metab* 1996;81:3379–3384.
- 33. Englund M, Haugen IK, Guermazi A, et al.** Evidence that meniscus damage may be a component of osteoarthritis: the Framingham study. *Osteoarthritis Cartilage* 2016;24:270–273.
- 34. Williams AA, Mancini NS, Solomito MJ, Nissen CW, Milewski MD.** Chondral injuries and irreparable meniscal tears among adolescents with anterior cruciate ligament or meniscal tears are more common in patients with public insurance. *Am J Sports Med* 2017;45:2111–2115.
- 35. Lane NE, Shidara K, Wise BL.** Osteoarthritis year in review 2016: clinical. *Osteoarthritis Cartilage* 2017;25:209–215.
- 36. Gersing AS, Schwaiger BJ, Nevitt MC, et al.** Is weight loss associated with less progression of changes in knee articular cartilage among obese and overweight patients as assessed with MR imaging over 48 months? Data from the osteoarthritis initiative. *Radiology* 2017;284:508–520.
- 37. Katz JN, Losina E.** Surgery versus physical therapy for meniscal tear and osteoarthritis. *N Engl J Med* 2013;369:677–678.
- 38. Sihvonen R, Paavola M, Malmivaara A, et al; Finnish Degenerative Meniscal Lesion Study (FIDELITY) Group.** Arthroscopic partial meniscectomy versus sham surgery for a degenerative meniscal tear. *N Engl J Med* 2013;369:2515–2524.
- 39. Yim J-H, Seon J-K, Song E-K, et al.** A comparative study of meniscectomy and nonoperative treatment for degenerative horizontal tears of the medial meniscus. *Am J Sports Med* 2013;41:1565–1570.
- 40. Herrlin SV, Wange PO, Lapidus G, Hållander M, Werner S, Weidenhielm L.** Is arthroscopic surgery beneficial in treating non-traumatic, degenerative medial meniscal tears? A five year follow-up. *Knee Surg Sports Traumatol Arthrosc* 2013;21:358–364.
- 41. Vermesan D, Prejbeanu R, Laitin S, et al.** Arthroscopic debridement compared to intra-articular steroids in treating degenerative medial meniscal tears. *Eur Rev Med Pharmacol Sci* 2013;17:3192–3196.
- 42. Katz JN, Wright J, Spindler KP, et al.** Predictors and outcomes of crossover to surgery from physical therapy for meniscal tear and osteoarthritis: a randomized trial comparing physical therapy and surgery. *J Bone Joint Surg Am* 2016;98:1890–1896.
- 43. Houck DA, Kraeutler MJ, Belk JW, McCarty EC, Bravman JT.** Similar clinical outcomes following collagen or polyurethane meniscal scaffold implantation: a systematic review. *Knee Surg Sports Traumatol Arthrosc* 2018;26:2259–2269.
- 44. Rodkey WG, DeHaven KE, Montgomery WH III, et al.** Comparison of the collagen meniscus implant with partial meniscectomy: a prospective randomized trial. *J Bone Joint Surg Am* 2008;90:1413–1426.

- 45. Verdonk P, Beaufils P, Bellemans J, et al; Actifit Study Group.** Successful treatment of painful irreparable partial meniscal defects with a polyurethane scaffold: two-year safety and clinical outcomes. *Am J Sports Med* 2012;40:844–853.
- 46. Vrancken AC, Buma P, van Tienen TG.** Synthetic meniscus replacement: a review. *Int Orthop* 2013;37:291–299.
- 47. Sun J, Vijayavenkataraman S, Liu H.** An overview of scaffold design and fabrication technology for engineered knee meniscus. *Materials (Basel)* 2017;10:29.
- 48. Kovacs BK, Huegeli R, Harder D, et al.** MR variability of collagen meniscal implant remodelling in patients with good clinical outcome. *Knee Surg Sports Traumatol Arthrosc* 2019; doi: 10.1007/s00167-019-05715-9. [Epub ahead of print].
- 49. Smith NA, Parkinson B, Hutchinson CE, Costa ML, Spalding T.** Is meniscal allograft transplantation chondroprotective? A systematic review of radiological outcomes. *Knee Surg Sports Traumatol Arthrosc* 2016;24:2923–2935.
- 50. Waugh N, Mistry H, Metcalfe A, et al.** Meniscal allograft transplantation after meniscectomy: clinical effectiveness and cost-effectiveness. *Knee Surg Sports Traumatol Arthrosc* 2019;27:1825–1839.
- 51. Novaretti JV, Patel NK, Lian J, et al.** Long-term survival analysis and outcomes of meniscal allograft transplantation with minimum 10-year follow-up: a systematic review. *Arthroscopy* 2019;35:659–667.
- 52. Barber-Westin SD, Noyes FR.** Low-impact sports activities are feasible after meniscus transplantation: a systematic review. *Knee Surg Sports Traumatol Arthrosc* 2018;26:1950–1958.
- 53. Elsner JJ, Shemesh M, Shefy-Peleg A, Gabet Y, Zylberberg E, Linder-Ganz E.** Quantification of in vitro wear of a synthetic meniscus implant using gravimetric and micro-CT measurements. *J Mech Behav Biomed Mater* 2015;49:310–320.
- 54. Elsner JJ, Portnoy S, Zur G, Guilak F, Shterling A, Linder-Ganz E.** Design of a free-floating polycarbonate-urethane meniscal implant using finite element modeling and experimental validation. *J Biomech Eng* 2010;132:095001.
- 55. Kopf S, Beaufils P, Hirschmann MT, et al.** Management of traumatic meniscus tears: the 2019 ESSKA meniscus consensus. *Knee Surg Sports Traumatol Arthrosc* 2020; doi: 10.1007/s00167-020-05847-3 [Epub ahead of print].
- 56. Tachibana Y, Mae T, Shino K, et al.** A longitudinal tear in the medial meniscal body decreased the in situ meniscus force under an axial load. *Knee Surg Sports Traumatol Arthrosc* 2019; DOI: 10.1007/s00167-019-05735-5 [Epub ahead of print].
- 57. Dean CS, Chahla J, Matheny LM, Mitchell JJ, LaPrade RF.** Outcomes after biologically augmented isolated meniscal repair with marrow venting are comparable with those after meniscal repair with concomitant anterior cruciate ligament reconstruction. *Am J Sports Med* 2017;45:1341–1348.
- 58. Everhart JS, Magnussen RA, Cavendish PA, et al.** Subjective knee function and risk of failure are equivalent for men and women at 5 years after meniscus repair. *Arthroscopy* 2020;36:816–822.
- 59. Stärke C, Kopf S, Gröbel K-H, Becker R.** The effect of a nonanatomic repair of the meniscal horn attachment on meniscal tension: a biomechanical study. *Arthroscopy* 2010;26:358–365.
- 60. Chung KS, Ha JK, Yeom CH, et al.** Comparison of clinical and radiologic results between partial meniscectomy and refixation of medial meniscus posterior root tears: a minimum 5-year follow-up. *Arthroscopy* 2015;31:1941–1950.
- 61. Feucht MJ, Kühle J, Bode G, et al.** Arthroscopic transtibial pullout repair for posterior medial meniscus root tears: a systematic review of clinical, radiographic, and second-look arthroscopic results. *Arthroscopy* 2015;31:1808–1816.
- 62. Kim SB, Ha JK, Lee SW, et al.** Medial meniscus root tear refixation: comparison of clinical, radiologic, and arthroscopic findings with medial meniscectomy. *Arthroscopy* 2011;27:346–354.
- 63. Lee JH, Lim YJ, Kim KB, Kim KH, Song JH.** Arthroscopic pullout suture repair of posterior root tear of the medial meniscus: radiographic and clinical results with a 2-year follow-up. *Arthroscopy* 2009;25:951–958.
- 64. Chung KS, Ha JK, Ra HJ, Kim JG.** A meta-analysis of clinical and radiographic outcomes of posterior horn medial meniscus root repairs. *Knee Surg Sports Traumatol Arthrosc* 2016;24:1455–1468.
- 65. Jing L, Liu K, Wang X, et al.** Second-look arthroscopic findings after medial open-wedge high tibial osteotomy combined with all-inside repair of medial meniscus posterior root tears. *J Orthop Surg (Hong Kong)* 2020;28:2309499019888836.
- 66. Edgar C, Kumar N, Ware JK, et al.** Incidence of posteromedial meniscocapsular separation and the biomechanical implications on the anterior cruciate ligament. *J Am Acad Orthop Surg* 2019;27:e184–e192.
- 67. Stephen JM, Halewood C, Kittl C, Bollen SR, Williams A, Amis AA.** Posteromedial meniscocapsular lesions increase tibiofemoral joint laxity with anterior cruciate ligament deficiency, and their repair reduces laxity. *Am J Sports Med* 2016;44:400–408.
- 68. Liu X, Zhang H, Feng H, Hong L, Wang X-S, Song G-Y.** Is it necessary to repair stable ramp lesions of the medial meniscus during anterior cruciate ligament reconstruction? A prospective randomized controlled trial. *Am J Sports Med* 2017;45:1004–1011.
- 69. Mithoefer K, McAdams T, Williams RJ, Kreuz PC, Mandelbaum BR.** Clinical efficacy of the microfracture technique for articular cartilage repair in the knee: an evidence-based systematic analysis. *Am J Sports Med* 2009;37:2053–2063.
- 70. Minas T, Gomoll AH, Rosenberger R, Royce RO, Bryant T.** Increased failure rate of autologous chondrocyte implantation after previous treatment with marrow stimulation techniques. *Am J Sports Med* 2009;37:902–908.
- 71. Vanlauwe J, Saris DB, Victor J, Almqvist KF, Bellemans J, Luyten FP; TIG/ACT/01/2000&EXT Study Group.** Five-year outcome of characterized chondrocyte implantation versus microfracture for symptomatic cartilage defects of the knee: early treatment matters. *Am J Sports Med* 2011;39:2566–2574.
- 72. Krych AJ, Harnly HW, Rodeo SA, Williams RJ III.** Activity levels are higher after osteochondral autograft transfer mosaicplasty than after microfracture for articular cartilage defects of the knee: a retrospective comparative study. *J Bone Joint Surg Am* 2012;94:971–978.
- 73. Bentley G, Biant LC, Vijayan S, Macmull S, Skinner JA, Carrington RW.** Minimum ten-year results of a prospective randomised study of autologous chondrocyte implantation versus mosaicplasty for symptomatic articular cartilage lesions of the knee. *J Bone Joint Surg Br* 2012;94:504–509.
- 74. Kolasinski SL, Neogi T, Hochberg MC, et al.** 2019 American College of Rheumatology/Arthritis Foundation guideline for the management of osteoarthritis of the hand, hip, and knee. *Arthritis Rheumatol* 2020;72:220–233.
- 75. Moran CJ, Pascual-Garrido C, Chubinskaya S, et al.** Restoration of articular cartilage. *J Bone Joint Surg Am* 2014;96:336–344.
- 76. Zhang H-F, Wang C-G, Li H, Huang Y-T, Li Z-J.** Intra-articular platelet-rich plasma versus hyaluronic acid in the treatment of knee osteoarthritis: a meta-analysis. *Drug Des Devel Ther* 2018;12:445–453.
- 77. Han Y-H, Huang H-T, Pan J-K, et al.** Comparison of platelet-rich plasma vs hyaluronic acid injections in patients with knee osteoarthritis: a protocol for a systematic review and meta-analysis. *Medicine (Baltimore)* 2018;97:e13049.

- 78. Phillips M, Vannabouathong C, Devji T, et al.** Differentiating factors of intra-articular injectables have a meaningful impact on knee osteoarthritis outcomes: a network meta-analysis. *Knee Surg Sports Traumatol Arthrosc* 2020; DOI: 10.1007/s00167-019-05763-1 [Epub ahead of print].
- 79. Wu Q, Luo X, Xiong Y, et al.** Platelet-rich plasma versus hyaluronic acid in knee osteoarthritis: a meta-analysis with the consistent ratio of injection. *J Orthop Surg (Hong Kong)* 2020;28:2309499019887660.
- 80. Brittberg M, Gomoll AH, Canseco JA, Far J, Lind M, Hui J.** Cartilage repair in the degenerative ageing knee. *Acta Orthop* 2016;87:26–38.
- 81. Martinez-Carranza N, Ryd L, Hulthenby K, et al.** Treatment of full thickness focal cartilage lesions with a metallic resurfacing implant in a sheep animal model, 1 year evaluation. *Osteoarthritis Cartilage* 2016;24:484–493.
- 82. Madonna V, Condello V, Piovan G, Screpis D, Zorzi C.** Use of the KineSpring system in the treatment of medial knee osteoarthritis: preliminary results. *Joints* 2016;3: 129–135.
- 83. Bode G, Kloos F, Feucht MJ, et al.** Comparison of the efficiency of an extra-articular absorber system and high tibial osteotomy for unloading the medial knee compartment: an in vitro study. *Knee Surg Sports Traumatol Arthrosc* 2017;25:3695–3703.